

## CASE REPORT

# A Case Report of Extrafamilial Child Homicide

Ma'rifatul Ula<sup>1</sup>, Abigael Samsi Pagatiku<sup>2</sup>, Ahmad Yudianto<sup>1</sup>

<sup>1</sup> Department of Forensic Medicine and Medicolegal, Faculty of Medicine, Universitas Airlangga, 60132 Surabaya. Indonesia

<sup>2</sup> Magister of Law, Faculty of Law, Universitas Hang Tuah, 60117 Surabaya. Indonesia

### ABSTRACT

Child abuse often occurs in Indonesia. In some extreme cases, mild or severe abuse might be accompanied by rape and homicide. Perpetrators of this violence can be anyone, including families, teachers, even parents. In this case report, we present the case of a child found in a muddy trench. On external examination, we found blisters on the arms and head, vulva without laceration in the hymen. Autopsy findings showed mud-filled pulmonary bronchi, esophagus, and stomach. The cause of death is determined asphyxia due to the closure of the airway by mud. Based on the crime scene examination and witness statements, the manner of death was upheld as a murder. Homicide is a criminal offense regulated in articles 338, 339, and 340 of the Indonesian Criminal Code. Whereas the homicide of children is held explicitly in the Child Protection Act.

**Keywords:** Child abuse, Drowning, Homicide, Forensic, Medicolegal

### Corresponding Author:

Ma'rifatul Ula, M.D

Email: ula.cat@gmail.com

Tel: (+62) 31- 5030255

### INTRODUCTION

Child death is always touching. However, child death due to lethal violence can provoke public anger, fear, and disgust. Interestingly, child homicide in this case report was carried out by a married couple who was supposed to have had the instinct to love a child.

Child homicide has been done in the past, referred to as infanticide. Infanticide was used to control family size, weed out weak, abnormal, deformed, and illegitimate children, and limit females (1). Child homicide as an extreme form of violence against children has recently become an essential global concern issue. Sustainable Development Goals on peace, justice, and strong institutions had it as a goal number 16 to "end abuse, exploitation, trafficking and all forms of violence against and torture children."

Although child murder is an important issue, data on the characteristics of such cases for the Asian region is still limited and for Indonesia as well. Indonesia Child Protection Commission (KPAI) data presentation on topics of murder against children - without the specific type of extra/intrafamilial murder and age - in Indonesia recorded 346 cases in the 2011-2016 period. That

means 4.13% of the 8,369 murder cases in Indonesia in the same period according to Indonesia Central Bureau of Statistics reports (BPS) (2).

Murder of children can be categorized as an intrafamilial and extrafamilial homicide. The categorization is based on the relationship between the perpetrator and the victim. Intrafamilial homicide is if the perpetrator is a biological parent, stepparent, guardian, or caregiver equal to the parents and a spouse. Thus, extrafamilial homicide meant that perpetrator is beyond the scope of intrafamilial homicide (1).

Extrafamilial child homicides included: Fatal sexual abuse: The killing of a child in the context of a sexual assault; and Other extra familial child homicides. Extrafamilial homicides were rare and only committed by male perpetrators. In the U.S., Jason (1983) suggested that there are two patterns of child homicide. The first is intrafamilial and predominates for victims aged 0-3 years and might be described as fatal child abuse. The second is extrafamilial and dominates with victims older than 12 years, and might be described as fatal parental-societal neglect. Between the ages of 3- and 12-years, homicide is a mixture of these two mentioned patterns (1).

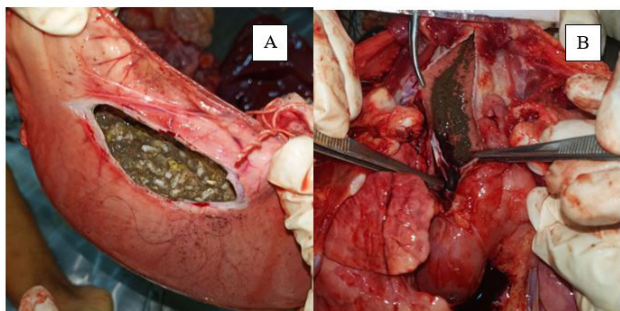
Child homicides, the extreme type of violence against children, are among the most challenging for forensic pathologists. From the point of view of forensic pathology, it is the most challenging case to

treat. There are many reasons, including the frequent absence of witnesses, accidental explanations are offered. There is often more than one carer spanning the period over which the injuries might have occurred, and there can be conflicting opinions between the various medical specialties. In Indonesia itself, there are rare reports of cases of child murder committed by married couples outside the nuclear family itself. In this paper, we report a child abuse case of a five-year-old girl who has been severely injured and ends in death.

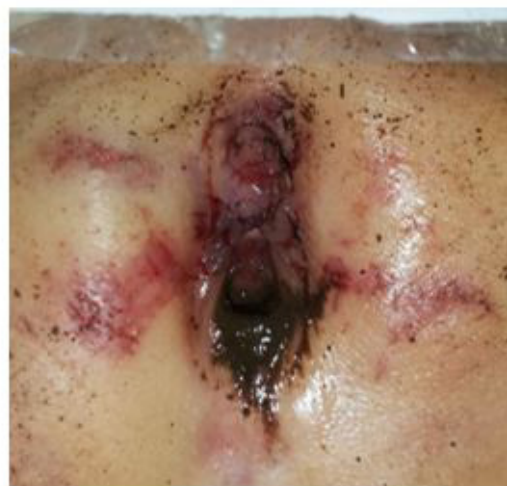## CASE REPORT

On Tuesday, July 7, 2020, the victim was taken to the suspect's house. According to the suspect's confession, the suspect took the victim to his place for play. At the time of the incident, the victim was first mistreated and molested. Then the victim was taken to a ditch and drowned to death. The suspect committed this act together with his wife. The victim was first found dead by residents at 01.00 pm in a ditch in the rice fields. The depth of the trench is about 50-70 cm. The victim is lying on her back and halfback. The victim was taken to the Forensic Medicine and Medicolegal Installation of Pusdik Bhayangkara Porong for external and internal examination. Along with the deceased, the postmortem request was included from Kepolisian Resort Pasuruan Sektor Kejayan with the number R/VER/03/2020/Polsek that we received on July 7, 2020, at 11.50 pm.

On the external examination, we found a sign of cyanosis on her nails from both hands and lips, along with bruises on her arms, chest, and all of her feet. We also found abrasion on her arm, neck, and anus. On genital examination, we found bruises and abrasion on her labia and clitoris, without laceration on hymen. All of the oral cavity, nose, genitals, and anus are filled with mud. Autopsy findings including blood absorption on the scalp, petechiae on the brain, mud all over the mouth, esophagus, trachea, and bronchial branches. Vaginal swab and irrigation show no sign of sperm or seminal fluid. The cause of death is established as drowning.



**Figure 1 : Stomach (A) and trachea (B) full with mud**



**Figure 2 : Bruise and laceration on genital including labia major, labia minor and clitoris.**

## DISCUSSION

Drowning is a mode of death that is difficult to prove at autopsy, so forensic pathologists make drowning a final diagnosis. Drowning in children is a form of child abuse (3). Manner of death in drowning in children is difficult to distinguish due to accident or murder. Many cases are not reported, or investigators cannot carry out investigations due to the lack of physical evidence, namely signs of resistance when the victim is drowned. This is due to differences in the size of the bodies of children and adults. There is a sign of struggle in adult bodies that was carried out when the victim was drowned (3).

Murder by drowning is usually without witnesses, and the victims are helpless children or toddlers. In previous research, it was stated that in the killing of children, they would be put in water and held until they were unconscious (3). In this case report, there was mud in the trachea, bronchioles, and stomach which proved that the victim was drowned, and the location of drowning was a trench.

The case of the child in this case report falls into the category of acute maltreatment in children. This means that the death of a child is directly related to injuries suffered due to abuse or neglect. Often in such cases, the child has never been previously abused. A perpetrator is generally a person known to the victim or the victim's closest person. Death to a child due to abuse is followed by a delayed time when the child suffers an injury and death that follows later (4). Injuries to the head, chest, and abdomen are common injuries in cases of fatal child abuse. The most frequent causes of death included blunt force head injury (40.4%), suffocation/strangulation (20.2%), and sharp force lung trauma (7.3%). The type of offenders, injury methods,

types of injuries, distribution of injuries, mechanism of death, and death causes were significantly different among victims of varying age groups. Eighteen (9.33%) victims displayed no external evidence of trauma. As conclusions: The patterns of injuries, death mechanisms, and causes of death were different among victims of varying age groups. A female predominance was noted among the victims aged 0–5 (4).

Apart from physical violence, this case was followed by sexual assault by the perpetrator. This act of sexual violence can be defined as any sexual act that is completed or attempted (unfinished), sexual contact with, or exploitation (i.e., non-contact sexual interaction) of a child. We diagnosed sexual abuse using WHO criteria if there was clear evidence of blunt force trauma or penetrating trauma to the hymen without any history of sexual copulation. However, we did not find sperm or seminal fluid in the vagina or body (5).

## CONCLUSION

Violence against children, both physically and sexually, is an act that is not justified because children are the future of the nation. Child abuse cases that ended in murders that the nuclear family did not commit are among the many cases that we often miss and are a challenge for forensic doctors, law enforcers, and the public. Reporting on violence against children needs to be socialized to reduce the number of child abuse. Legal protection measures for children need to be empowered to protect

children from violence, exploitation, and neglect.

## ACKNOWLEDGEMENT

The authors express their gratitude to the Department of Forensic Medicine and Medicolegal, Faculty of Medicine, Universitas Airlangga who has given their permission for the authors conduct research, guided the authors and all the participants who were involved.

## REFERENCES

1. Somander LKH, Rammer LM. Intra- and Extrafamilial Child Homicide in Sweden 1971-1981. *Child Abuse Negl.* 1991;15:45–55.
2. Komisi Perlindungan Anak Indonesia. <https://bankdata.kpai.go.id/tabulasi-data/data-kasus-se-indonesia/data-kasus-perlindungan-anak-berdasarkan-lokasi-pengaduan-dan-pemantauan-media-se-indonesia-tahun-2011-2016>. 2016. p. 2016.
3. Somers GR, Chiasson DA, Smith CR. Pediatric drowning: A 20-year review of autopsied cases: II. Pathologic features. *Am J Forensic Med Pathol.* 2006;27(1):20–4.
4. Hwa HL, Pan CH, Shu GM, Chang CH, Lee TT, Lee JCI. Child homicide victims in forensic autopsy in Taiwan: A 10-year retrospective study. *Forensic Sci Int [Internet]*. 2015;257:413–9. Available from: <http://dx.doi.org/10.1016/j.forsciint.2015.10.020>
5. Chiesa A, Goldson E. Child sexual abuse. *Pediatr Rev.* 2017;38(3):105–18.